

Green urine color due to methylene blue

Metilen mavisine bağlı meydana gelen yeşil idrar

Faruk Özgör, Abdulmuttalip Şimşek, Metin Savun, Ömer Sarılar, Mehmet Fatih Akbulut, Zafer Gökhan Gürbüz

Haseki Eğitim ve Araştırma Hastanesi, Üroloji Kliniği, İstanbul

Geliş tarihi (Submitted): 18.07.2015

Kabul tarihi (Accepted): 24.11.2015

Yazışma / Correspondence

Abdulmuttalip Şimşek

Haseki Eğitim ve Araştırma Hastanesi

Üroloji Kliniği- 34096

Tel: 0212 529 44 00

E-mail: simsek76@yahoo.com

Özet

İdrarda meydana gelen renk değişikliği üriner sistem hastalıkları için önemli bir işarettir ve üriner infeksiyonlar, tümörler, taşlar ve benign prostat hiperplazisi ile ilişkilidir. Buna rağmen tüketilen besinler, boyalar, hemaglobin, bilirubin ve ürik asit metabolizma ürünleri gibi bazı tehlikesiz durumlarda idrar rengi değişikliğine yol açabilmektedir. Bu karmaşık durum gereksiz araştırmalara yol açabilir. Bu çalışmada metilen mavisinin alınmasından sonra meydana gelen yeşil idrarı sunmayı amaçladık. Metilen mavisinin ile ilişkili olarak oluşan yeşil idrar tehlikesiz bir durumdur ve bunun akılda tutulması gereksiz laboratuvar testlerinden kaçınılmasını sağlayacaktır.

Anahtar Kelimeler: metilen mavisi, propofol, yeşil idrar

Abstract

Discoloration of urine is an important sign of urinary system disorders and is associated with urinary infections, tumors, stones and benign prostatic hyperplasia. However, some benign conditions such as ingested substances, dyes, hemoglobin, bilirubin and products of uric acid metabolism may lead to discoloration of urine. This complex situation can lead to unnecessary investigations. In this study, we aim to report a case of green discoloration of urine after ingestion of methylene blue. Green urine associated with methylene blue is a benign condition and it is important to avoid performing unnecessary laboratory tests.

Keywords: methylene blue, propofol, green urine

Çıkar Çatışması: Yazarlar çıkar çatışması bildirmemişlerdir.

Finansal Destek: Yazarlar bu çalışma için finansal destek almadıklarını beyan etmişlerdir.

Conflict of Interest: No conflict of interest was declared by the authors.

Financial Support: The authors declare that this study received no financial support.

Introduction

For centuries, physicians have diagnosed patient diseases by assessing urine samples, and approximately 20 different urine colors have been reported until today ^[1]. Changes in urine color may be associated with structural, infectious and/or malignant disorders in the urinary system, digestive system or respiratory tract. Whatever the reason, discoloration of urine is a cause for alarm both to the physician and patient. Occasionally, discoloration of urine may be attributed to benign situations such as, ingested substances, dyes or from endogenous metabolic products including hemoglobin, myoglobin, bilirubin, and uric acid ^[1,3].

In literature, most reports about green discoloration of the urine were due to propofol infusion, while green discoloration caused by methylene blue was relatively less reported. In this paper, we aim to report a case of green discoloration of urine after ingestion of methylene blue for examining gastrointestinal fistula.

Case Report

A 74 year-old man visited the emergency department with a complaint of inability to urinate for eight hours. In his physical examination, globe vesicale and suprapubic sensitivity were detected with palpation. The globe vesicale was confirmed via ultrasonographical imaging and the patient was diagnosed as having acute urinary retention without any sign of hydronephrosis. Written informed consent was obtained from the patient for catheter insertion. After 18 F Foley catheter insertion, green discoloration of urine was observed (Figure 1). The laboratory findings and urinalysis were normal. The urine returned to its normal color within three hours. In his medical history, the patient had a diagnosis of inoperable gastric cancer and a jejunostomy performed two months ago. Three days before, methylene blue was administered for detecting entero-cutaneous fistula; however, no fistula was reported. There was no medication use other than methylene blue. An alpha blocking agent was prescribed and the patient was referred to the urology outpatient clinic to investigate the etiology of acute urinary retention.

Discussion

Here, we presented the first case in Turkey of discoloration of urine to a green color associated with the use

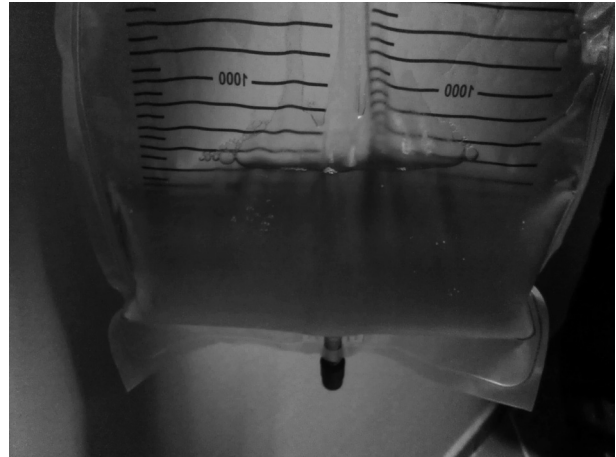


Figure 1: The patient urine sample.

of methylene blue. Green discoloration of urine is mostly due to medications such as propofol, cimetidine, metoclopramide, amitriptyline, and indomethacin, or the ingestion of dyes including methylene blue and indigo blue. Infections such as *Pseudomonas aeruginosa* also lead green urine ^[1,2,4].

Methylene blue is a water soluble dye, which is commonly used as a marker to detect leakage in various tissues, and it is excreted as leucomethylene blue by the kidneys which may change the urine color to bluish or greenish without any associated pathological effect. ^[1,4] In the present case, methylene blue was administered with the aim detecting entero-cutaneous fistula. In literature, the green discoloration of urine is frequently seen after propofol use and seems to be independent of the dosage and length of administration. ^[4,5] Likewise, greenish discoloration of urine due to methylene blue is consistently reported after a unique dose of methylene blue. The onset of greenish discoloration of urine after methylene blue is inconsistent in literature ^[6]. In our case, the discoloration due to methylene blue started after three days, returned to normal within three hours.

Although the green urine associated with methylene blue is uneventful, urgent diagnosis of this rare adverse-affect may help to avoid unnecessary laboratory tests. Thus, physicians should keep methylene blue in mind when taking anamnesis of a patient with a sudden discoloration of green urine particularly those with a suspicion of fistula.

References

1. Lepenies J, Toubekis E, Frei U, Schindler R. Green urine after a motorcycle accident. *Nephrol Dial Transplant* 2000; 15: 725-6.
2. Shim YS, Gil HW, Yang JO, Lee EY, Kim SH, Hong SY. A case of green urine after ingestion of herbicides. *Korean J Intern Med* 2008;23: 42-4.
3. Gillett MJ, Burnett JR. Medications and green urine. *Intern Med J* 2006;36: 64-6.
4. Tan CK, Lai CC, Cheng KC. Propofol-related green urine. *Kidney Int* 2008;74: 978.
5. Lee JS, Jang HS, Park BJ. Green discoloration of urine after propofol infusion. *Korean J Anesthesiol* 2013;65: 177-9.
6. Stratta P, Barbe MC. Images in clinical medicine. Green urine. *N Eng J Med* 2008; 358: e 12.