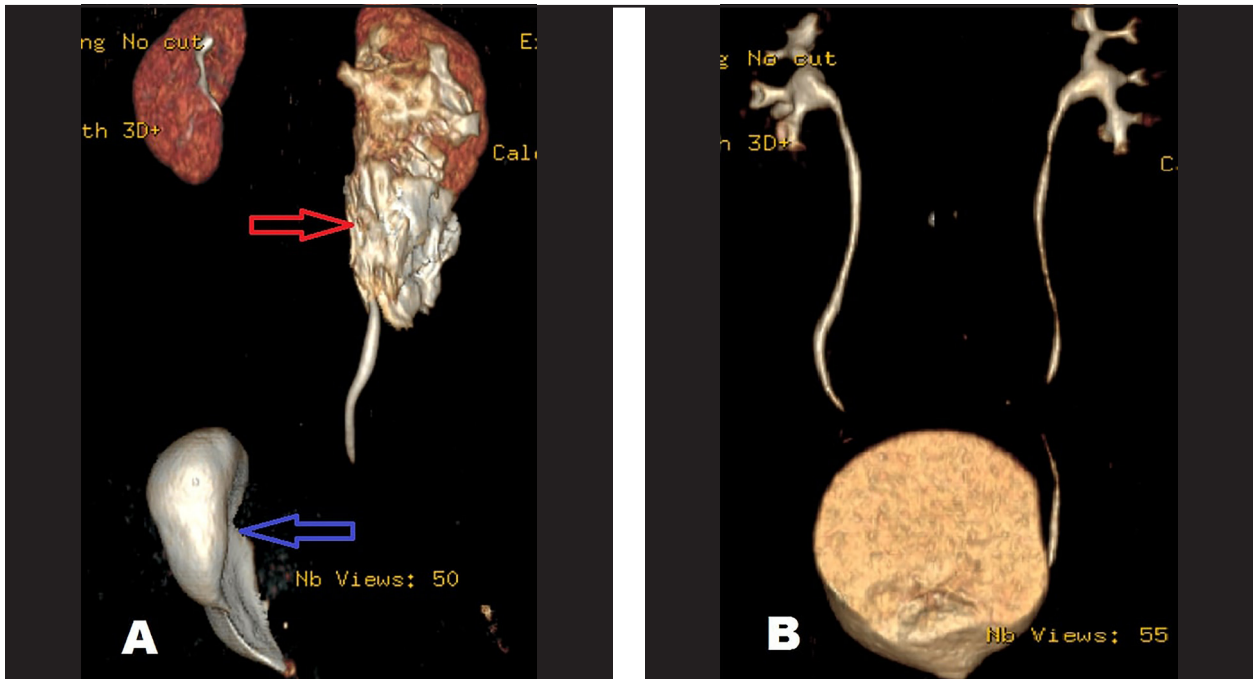


YENİ ÜROLOJİ DERGİSİ

The New Journal of Urology



Akyüz O, Ergün M, Dölek N, Çam K. Spontaneous severe retroperitoneal hemorrhage with concomitant renal pelvis rupture during the course of COVID-19 infection: a case report. The New Journal of Urology 2022; 17(2):98-103.

Micro V Doppler assessment of testicular blood supply in the pediatric age population: may reduce the need for senior guidance in the evaluation of prepubertal torsion

Samet Şimşek, Mehmet Karagülle, Fatma Zeynep Arslan, Süleyman Öncü, Mehmet Öncü, Ahmet Tan Cimilli

The effects of social isolation measures taken against the COVID-19 pandemic on erectile functions of healthcare professionals: a prospective comparative study

Ahmet Emre Cinislioğlu, Emre Şam, Nazan Cinislioğlu, Şaban Oğuz Demirdöğen, İbrahim Karabulut, Fatih Akkaş, Elif Özcan, İbrahim Hakkı Tor, İsa Özbey

Does bladder wall thickness have a place in the evaluation of male patients with lower urinary tract symptoms?

Özgür Ekici, Soner Çoban, Abdullah Gül, Erkan Büyükdemirci, Salim Zengin, Çağlar Boyacı

Assessment of associated factors with nocturia in young and older urinary incontinent

Mustafa Soytaş, Rabia Bağ Soytaş

Spontaneous severe retroperitoneal hemorrhage with concomitant renal pelvis rupture during the course of COVID-19 infection: a case report

Osman Akyüz, Müslüm Ergün, Naile Dölek, Kamil Çam

Sphenoid wing metastasis of prostate cancer: a rare case

Fatih Akdemir

Is it time to stage prostate cancer using molecular imaging?

Özer Güzel, Fazlı Polat, Ali Atan

Active surveillance of prostate cancer with multiparametric magnetic resonance imaging: Review of the literature

Fatih Yanaral, Ufuk Çağlar, Furkan Şendoğan, Murat Binbay