

Interstitial pneumonia: A rare complication after intravesical Mitomycin-C treatment for bladder tumor

İnterstisyel pnömoni: Mesane tümörü için uygulanan mesane içi Mitomycin-C tedavisinden sonra gelişen nadir bir komplikasyon

Adem Emrah Coguplugil¹, Alper Gundogan², Nesrin Ocal², Ibrahim Yildirim¹, Seyfettin Gumus², Turgay Ebiloglu¹, Zafer Demirer¹, Engin Kaya¹, Giray Ergin¹

¹Department of Urology, Gulhane Military Medical Academy, Ankara, Turkey

²Department of Respiratory Medicine, Gulhane Military Medical Academy, Ankara, Turkey

Özet

Transüretral mesane tümörü rezeksiyonu sonrası mesane içi Mitomycin-C instilasyonu başlanan 66 yaşında bir erkek hastada interstisyel pnömoni gelişti. Hastaya haftalık 40 mg mesane içi Mitomycin-C uygulanmıştı ve üçüncü uygulamadan 4 gün sonra hasta acil servise ilerleyici dispne şikayeti ile başvurdu. Çekilen yüksek çözünürlüklü toraks tomografisinde akciğerin sağ üst ve her iki alt loblarında buzlu cam görüntüsü, iki taraflı plevral efüzyon ve interlobuler septal kalınlaşma görüntüledi. Akciğer infeksiyonu ve kollajen vasküler hastalıklar dışlandı. İnterstisyel pnömoni öntanısıyla Mitomycin-C tedavisinin bırakılıp prednizolon tedavisi başlanmasıyla semptomatik ve radyolojik iyileşme sağlandı. Mesane içi Mitomycin-C interstisyel pnömoni gibi nadir sistemik yan etkilere neden olabilir.

Anahtar Kelimeler: Mitomisin; Akciğer Hastalıkları, İnterstisyel; Pnömoni; Mesane neoplazileri

Abstract

Sixty six years-old male patient, who underwent transurethral resection of bladder tumor and consequent intravesical Mitomycin-C chemotherapy, developed interstitial pneumonia. Forty mg intravesical Mitomycin-C was instilled weekly. Four days after the third instillation, the patient presented to emergency service with the complaint of progressive dyspnea. High resolution thorax tomography demonstrated ground glass opacity in the right upper and bilateral lower lobes, bilateral pleural effusion and interlobular septal thickening. Infection and collagen vascular disease were excluded. Symptomatic and radiological improvement achieved with discontinuation of intravesical Mitomycin-C and initiation of prednisolone treatment. Intravesical Mitomycin-C may cause rare systemic side effects like interstitial pneumonia.

Keywords: Mitomycin; Lung Diseases, Interstitial; Pneumonia; Urinary Bladder Neoplasms

Geliş tarihi (Submitted): 18.03.2016

Kabul tarihi (Accepted): 01.05.2016

Yazışma / Correspondence

Adem Emrah Coguplugil
Department of Urology, Gulhane
Military Medical Academy,
Ankara, Turkey
Phone: +90 530 380 9524
Fax: +90 312 304 5627
E-mail: aemrahco@yahoo.com

Bu yazının özeti 26-30 Ekim 2011 tarihlerinde yapılan Üroonkoloji Kongresi'nde poster bildirisi olarak sunulmuştur.

Introduction

Mitomycin-C (MMC) is a chemotherapeutic agent that is derived from streptomyces caespitosis. MMC has been used in the treatment of various solid tumors including breast, bladder and non-small cell lung cancer (1). Instillation of MMC into the bladder (intravesical MMC chemotherapy) has been shown to decrease the risk of recurrence of bladder tumor and widely performed following transurethral resection of bladder tumor (TURBT) (2). Various toxic reactions related to MMC is described including renal, cardiac and pulmonary toxicity (1). The incidence of pulmonary toxicity after systemic MMC chemotherapy is likely to be less than 10% (3). On the other hand, intravesical MMC chemotherapy is recognized as a safer treatment than systemic MMC chemotherapy since the urothelium serves as a barrier that limits the absorption of drugs into systemic circulation (4). Therefore, systemic pulmonary toxicity related to intravesical MMC chemotherapy is rare and limited to few case reports (4-7). Here we report a case of interstitial pneumonia that developed after intravesical MMC instillation.

Case Report

Sixty six years-old male patient undergoing hemodialysis for 9 months due to chronic kidney disease (CKD) presented to our clinic with macroscopic hematuria. Bladder cancer located in the right lateral bladder wall was detected on diagnostic Cystoscopy (approximately 1 cm single, papillary tumor) and TURBT was performed. MMC 40 mg was instilled into the bladder 4 hours after TURBT. Pathological examination reported low grade papillary urothelial carcinoma (pT1) and continuation of intravesical MMC was decided (40 mg/week for 6 weeks). Intravesical 40 mg/week MMC instillation was initiated 2 weeks after TURBT. Symptomatic urinary tract infection (UTI) was occurred following second MMC instillation and treated appropriately according to urine culture and antibiogram results (Ertapenem 1000 mg/day for 10 days). And then, third MMC instillation was performed after obtaining normal urine culture.

The patient was presented to emergency service with the complaint of progressive dyspnea, which developed 4 days after the third MMC instillation. He had no history of drinking and previous respiratory disease and had not been exposed to any toxic dusts, fumes, asbestos, birds or

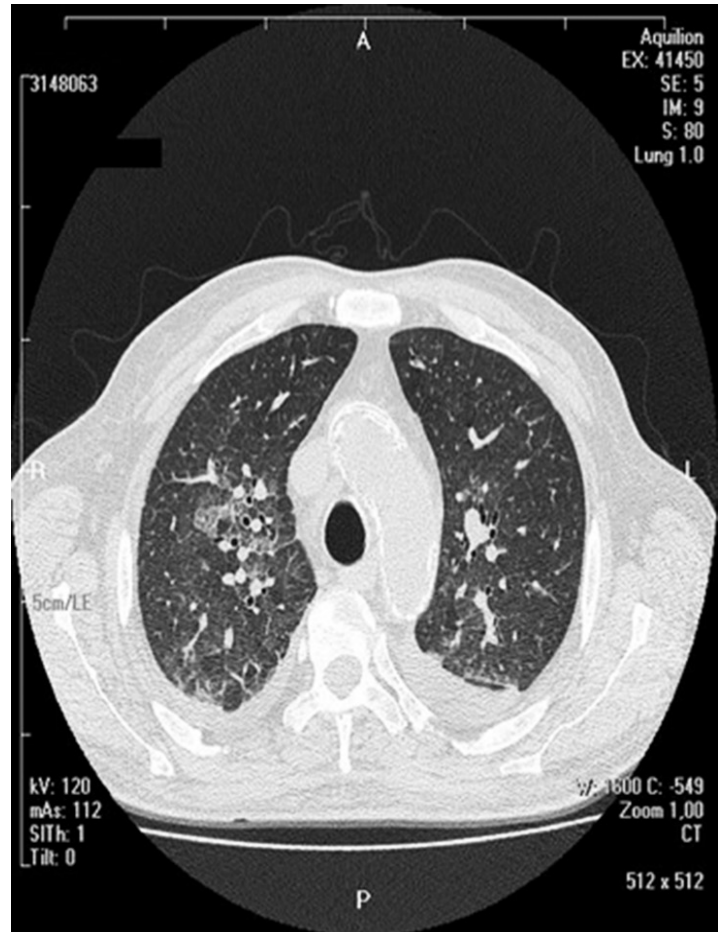


Figure 1. High resolution thorax tomography demonstrated ground glass opacity in the bilateral lower lobes, bilateral pleural effusion and interlobular septal thickening.

other animals. He gave up smoking 9 months ago (110 packet/year). He had a history of CKD and controlled diabetes mellitus. Preoperative chest x-ray did not show any evidence of interstitial pneumonia. His body temperature was 36.7 °C, blood pressure was 130/70 mmHg, pulse rate was 90 beats/min. and respiratory rate was 21 times/min. Findings on chest examination revealed inspiratory crackles over the bilateral lung fields, especially on the right side. Arterial blood gas analysis showed SaO₂:66.1%, PaO₂:41.6 mmHg, PaCO₂:30.3 mmHg and HCO₃:20.8 mmol/L. Laboratory data on admission was as follows: Hb,9.3 g/dl; white blood cell count, 8.4x10³/microL (74.9% neutrophil, with no eosinophilia). Arterial blood gas analysis at rest with 2 L/min of oxygen showed SaO₂:83.3%, PaO₂:49.7 mmHg, PaCO₂:28.6 mmHg and HCO₃:21.5 mmol/L.

As consistent with interstitial pneumonia, high resolution thorax tomography demonstrated ground glass opacity in the right upper and bilateral lower lobes, bilateral pleural effusion and interlobular septal thickening (figure 1). Bronchoscopy did not performed due to respiratory failure. Collagen vascular disease and infection were excluded by negative serologic markers, clinical and laboratory findings inconsistent with infection and broad spectrum antibiotic treatment due to UTI 7 days before the respiratory failure. The clinical condition was assessed as acute interstitial pneumonia and non-invasive mechanic ventilation was performed with intravenous prednisolone administration (3-day course of 1000 mg/day and then 60 mg/day). MMC treatment was discontinued. Respiratory failure was fully recovered and the radiological findings were almost completely recovered 10 days after the initiation of the prednisolone treatment. After clinical and radiological improvement the patient was discharged to home.

Discussion

Systemic pulmonary toxicity after intravesical MMC chemotherapy is rarely expected as a result of the barrier function of urothelium that limits the absorption of drugs into systemic circulation. Therefore, intravesical MMC chemotherapy is considered as a safer treatment (4). In the literature, there are few reports regarding pulmonary side effects of intravesical MMC chemotherapy (4-7). On the other hand, interstitial pneumonia induced with intravenous MMC is a known clinical condition. Also, MMC therapy is a potent inducer of pulmonary veno-occlusive disease in humans, which is characterized by obstruction of small pulmonary veins (8). The incidence of pulmonary toxicity after systemic MMC chemotherapy is likely to be less than 10% (3).

The symptoms of MMC induced pulmonary toxicity are progressive dyspnea and a dry cough and the pathological features are as follows: diffuse alveolar damage, acute permeability edema, and pulmonary fibrosis (4). MMC induced pulmonary toxicity was first described by Orwoll et al (5). They reported the histologically characteristic features as: diffuse alveolar septal edema, mononuclear-cell interstitial infiltrates, hypertrophy of alveolar lining cells, and alveolar septal collagen deposition. Wada et al described a case of pathologically confirmed

interstitial pneumonia due to intravesical MMC chemotherapy (4). They reported the pathological findings as: strong pleural adhesions in the right lung and hemorrhage in the left lung, hyaline membrane with marked fibrin deposition, desquamated alveolar epithelium, bleeding into the alveolar space, infiltration of inflammatory cells to the alveolar walls, and thickening of the alveolar walls.

In our case, MMC induced lung toxicity was occurred 4 days after the third intravesical MMC instillation. We diagnosed interstitial pneumonia induced with intravesical MMC by history, laboratory and radiological findings, negative serologic markers and clinical course. MMC therapy was discontinued after the diagnosis of interstitial pneumonia. In accordance with the literature, prednisolone treatment rapidly improved symptoms and radiological findings (9-11).

It must be kept in mind that intravesical mitomycin C may cause rare systemic side effects like interstitial pneumonia, despite the barrier function of the urothelium that limits the absorption of drugs into systemic circulation.

Acknowledgement

None

Conflict of interest

None

References

1. Castro M, Veeder MH, Mailliard JA, Tazelaar HD, Jett JR. A prospective study of pulmonary function in patients receiving mitomycin. *Chest* 1996;109:939-44.
2. Shapiro O, Jones K, Wang C, Landas S, Haas GP. Risk of post-operative intravesical mitomycin C instillation following transurethral bladder tumor resection. *Can J Urol* 2006;13:3317-20.
3. Verweij J, van Zanten T, Souren T, Golding R, Pinedo HM. Prospective study on the dose relationship of mitomycin C-induced interstitial pneumonitis. *Cancer* 1987; 60:756-61.
4. Wada H, Nakano Y, Yamada H, Saiga T, Yamanaka A, Sakai N. Intravesical Mitomycin-C Induced Interstitial Pneumonia. *Respiration* 2010;80:256-259.
5. Orwoll ES, Kiessling PJ, Patterson JR. Interstitial pneumonia from mitomycin. *Ann Intern Med* 1978 ;89:352-5.
6. Wilhelms E, Cri e CP, Neubauer H, Neuhaus KL. Lung parenchyma disease following instillation of mitomycin C in the bladder. *Dtsch Med Wochenschr* 1986;111:1564-6.
7. Neubauer H, Blech M, Wilhelms E, Cri e CP, Neuhaus KL,

- Truss F. Pulmonary fibrosis following instillation of mitomycin C in the urinary bladder. *Urologie A* 1987;26:41-3.
8. Perros F, Günther S, Ranchoux B, et al. Mitomycin-Induced Pulmonary Veno-Occlusive Disease: Evidence From Human Disease and Animal Models. *Circulation* 2015;132:834-47.
 9. Yoon JM, Rao U, Vassilopoulos PP, Ledesma E, Mittelman A. Interstitial pneumonitis associated with mitomycin C and DTIC: a case report. *Med Pediatr Oncol* 1981;9:61-7.
 10. Okuno, SH, Frytak S. Mitomycin Lung Toxicity: Acute and Chronic Phases. *Am J Clin Oncol* 1997; 20: 282–284.
 11. Linette DC, McGee KH, McFarland JA. Mitomycin-induced pulmonary toxicity: case report and review of the literature. *Ann Pharmacother* 1992; 26:481-4.